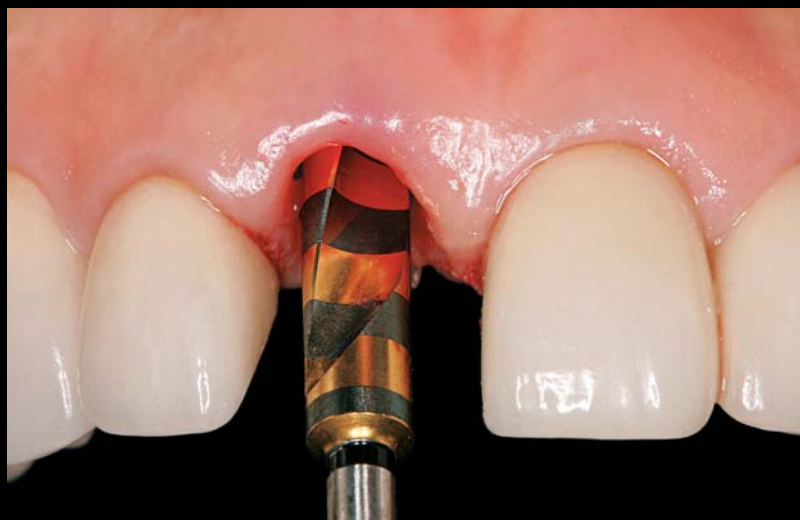

# MODIFIED DRILLING SEQUENCE FOR IMMEDIATE LOADING OF NON-CONICAL SINGLE IMPLANTS PLACED IN EXTRACTION SOCKETS

Ernesto A. Lee, DMD, Dr.Cir.Dent. • Huan Su, DDS† • Oscar González-Martín, DDS‡



*In the aesthetic zone, implant placement into a fresh extraction socket may be advantageous when followed by the immediate placement of a provisional restoration. The immediate loading of single implants, however, does represent a higher risk since the occlusal forces may induce micromotion that will ultimately lead to implant failure. A protocol is presented to enhance stability during immediate placement and immediate loading of implants exhibiting a non-conical apical design into fresh extraction sockets.*

## Learning Objectives:

This article describes a surgical rationale and procedure for immediately placed single-tooth implants in postextraction sockets. Upon reading and completing this exercise, the reader should:

- Be able to identify the critical factors that are required to ensure successful outcomes in immediately loaded single-tooth implants.
- Gain understanding of the aesthetic advantages of placement of implants into fresh extraction sockets.

**Key Words:** *implant, surgery, immediate, postextraction, socket, drilling, osteotomy*

\*Director, Postdoctoral Periodontal Prosthesis Program and Clinical Professor, Department of Periodontics, University of Pennsylvania School of Dental Medicine, Philadelphia, PA; private practice, Bryn Mawr, PA.

†Former Resident, Postdoctoral Periodontal Prosthesis, University of Pennsylvania School of Dental Medicine, Philadelphia, PA; private practice, Seattle, WA.

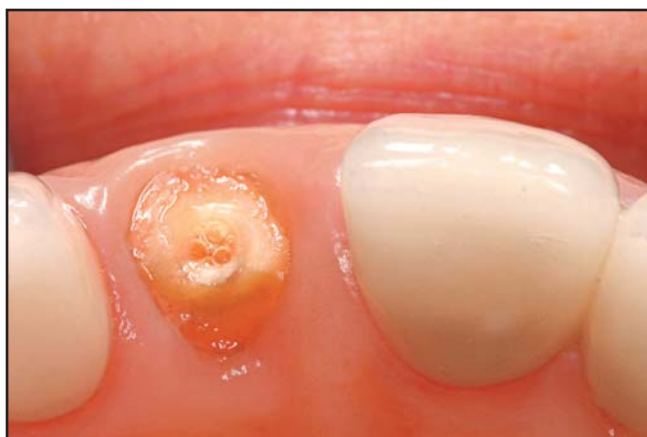‡Former Resident, Postdoctoral Periodontal Prosthesis, University of Pennsylvania School of Dental Medicine, Philadelphia, PA; ITI fellow, Geneva, Switzerland.

Ernesto A. Lee, DMD, Dr.Cir.Dent, 976 Railroad Avenue, Suite 200, Bryn Mawr, PA 19010  
Tel: 610-525-1200 • Email: drernestolee@gmail.com

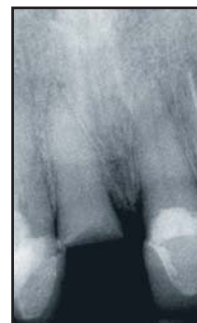Dental implant manufacturers have developed specific drilling sequences to ensure optimum results with respect to osseointegration. The recommended drilling procedure, however, accounts for clinical applications where traditional implant loading protocols (which include a healing period prior to restoring the implant and subsequent exposure to occlusal forces) will be followed.

The immediate loading of dental implants may be successfully achieved following certain guidelines. Several authors have demonstrated high success rates in situations where multiple implants are immediately loaded and splinted with a full-arch fixed prosthesis.<sup>1,3</sup> The rationale for this procedure is grounded in the fact that the cross-arch stabilization provided by the splinted prosthesis limits implant movement, thus preventing fibrous proliferation along the implant surface and allowing osseointegration to result in adequate bone-to-implant contact.

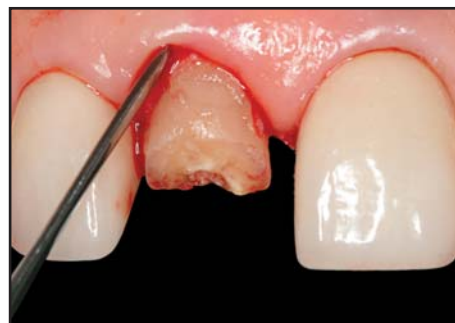Ganeles and Testori reported high success rates in full-arch mandibular and maxillary immediate loading cases utilizing implant insertion torque values of 25 Ncm.<sup>4,5</sup> There are, however, few guidelines with respect to the immediate loading of single implants, where splinting is not available as a mechanism to ameliorate the application of occlusal forces.



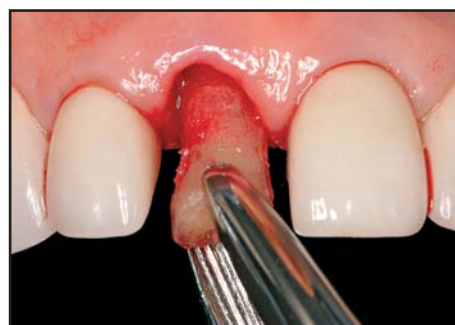**Figure 1.** A 52-year-old female with a high smile line presented with fractured tooth #8(11). Adjacent restorations are functionally adequate and aesthetically acceptable.



**Figure 2.** Preoperative radiograph of fractured #8. Restoration will require endodontic therapy, forced eruption, and/or crown lengthening.



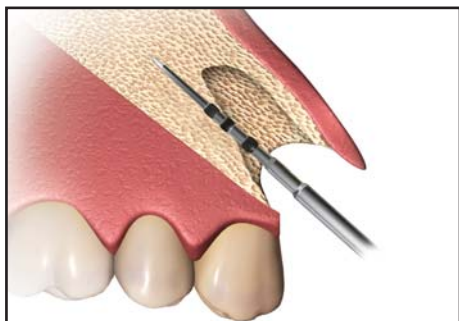
**Figure 3.** The periotome technique is utilized to remove the tooth fragment, with the objective of minimizing soft tissue trauma.



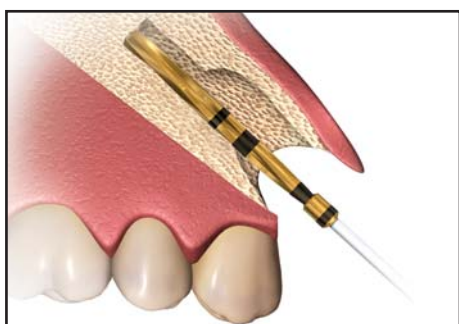
**Figure 4.** Preservation of the socket and an intact buccal plate are essential for immediate placement and maintenance of peri-implant bone and soft tissue levels.

### Immediate Postextraction Placement and Provisionalization of Single Implants

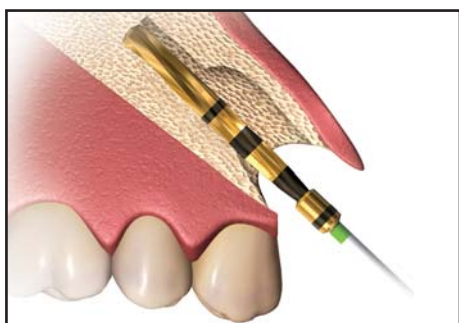
It is a well-established fact that tooth extraction will result in resorption of the alveolar ridge.<sup>6</sup> Although major changes occur through a 12-month period following tooth extraction, two thirds of the reduction in ridge dimension will occur within the first three months.<sup>7,8</sup> Periodontal ligament fibers insert into the cementum on



**Figure 5.** A precision drill is recommended to initiate the osteotomy on the palatal wall of the alveolar socket.



**Figure 6.** The site is subsequently drilled beyond the apical region until the precise depth required by the selected implant length is achieved.



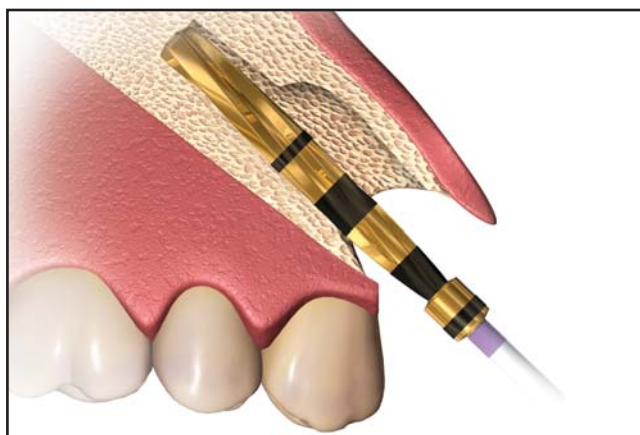
**Figure 7.** Subsequent shaping drills should be utilized while applying palatal pressure to prevent the osteotomy from migrating labially through the drilling sequence.

the tooth side, and into bundle bone on the alveolar side. This bundle bone is lost as a result of the resorptive process following tooth extraction. The degree of bone remodeling will be dependent on the periodontal biotype.<sup>9</sup> The presence of a thicker facial plate may limit the amount of alveolar crest height that is lost due to bone remodeling following tooth extraction. Conversely, patients with thin biotypes exhibit a narrower labial plate

that is comprised of a proportionally higher amount of bundle bone, thus leading to an increased loss of vertical alveolar ridge height postextraction.

Placement of a dental implant into a fresh extraction socket has been proposed as a viable alternative to the traditional delayed approach, and several authors have reported acceptable success rates with immediate placement techniques.<sup>10,11</sup> That such a procedure can be utilized as a means of preventing the alveolar and gingival remodeling that will occur as a result of tooth removal remains controversial. Although the assumption that implant placement will prevent bone resorption following extraction continues to be advanced by many clinicians, animal research appears to indicate that this is not the case, at least in the dog model.<sup>9,12</sup>

Placement of a provisional restoration at the time of implant placement has also been advocated to preserve the gingival tissue height and profile. The current rationale is based on the idea that the temporary restoration will support the soft tissue contours, thus avoiding collapse of the gingival margin and interproximal papillae.<sup>13-15</sup> An alternative technique includes the use of a transitional custom abutment in conjunction with the placement of a provisional restoration.<sup>16</sup> Available clinical data and experience appears to support the validity of this protocol.



**Figure 8.** The second-to-last drill is utilized to prepare the entire length of the osteotomy. Mesiodistal drill orientation should concur with the long axis of the future restoration.

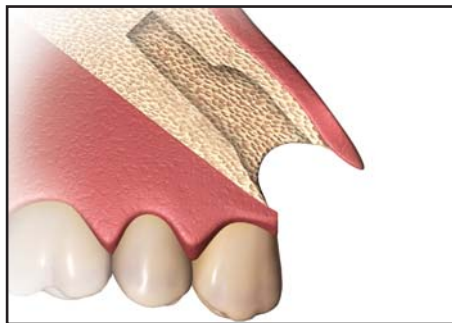
While immediate loading of a full-arch prosthesis has been shown to be a viable approach,<sup>1,4,5</sup> the immediate loading of single implants requires additional considerations. Since splinting cannot be counted on to control occlusal forces under these circumstances, implants placed into extraction sockets that are immediately loaded may require a higher degree of stability to prevent micromotion and fibrous tissue proliferation along the implant surface, which may result in decreased bone-to-implant contact and potential fixture failure. Nevertheless, minimum insertion torque requirements for the successful integration of immediately loaded single-tooth implants placed into fresh extraction sockets remain to be determined. Reports by Wörhle<sup>13</sup> and Cannizaro et al<sup>17</sup> suggest that insertion torques of 45 Ncm seem adequate in terms of achieving sufficient primary stability for immediate loading of single-tooth implants. Conversely, Pinheiro Ottoni et al reported a high degree of failures when implants were placed at 20 Ncm and immediately loaded.<sup>18</sup>

### Treatment Objectives

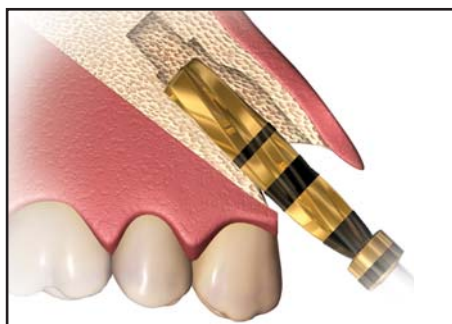
The following protocol was developed with the purpose of increasing the insertion torque and stability of implants exhibiting a non-conical apical design placed into fresh extraction sockets. Additionally, it should enable clinicians to pursue immediate loading with a provisional restoration.

### Surgical Guidelines

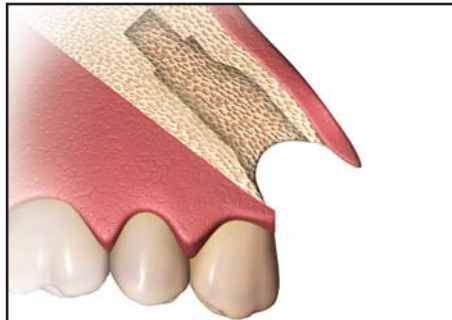
Implant osteotomy preparation in fresh extraction sockets may present technical challenges. Often times, the clinician may choose not to follow the orientation of the extracted tooth, which requires the surgical preparation of an alveolar wall. Additionally, immediate postextraction placement in the aesthetic zone often requires that the implant be placed in a more lingual (ie, palatal) position. Either of the former scenarios includes osteotomy drilling that must be performed on the inclined



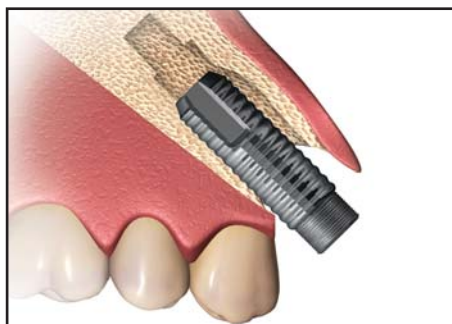
**Figure 9.** Implants with a conical apex may be placed into the undersized osteotomy at this stage.



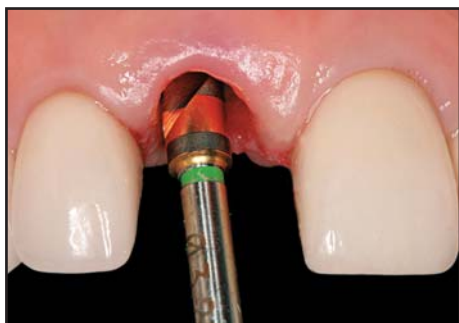**Figure 10.** Final drill is utilized to a depth equivalent to two thirds of the selected implant length, while widening the osteotomy.



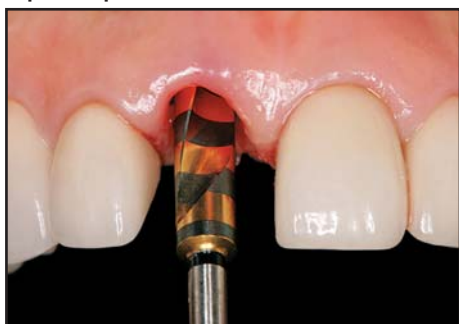**Figure 11.** The underprepared apical third of the osteotomy provides enhanced primary stability to allow immediate loading of single implants.



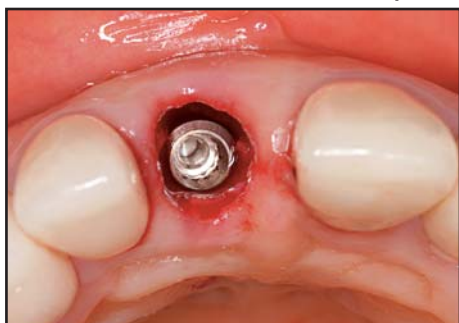**Figure 12.** Insertion torque of 45 Ncm is recommended. The implant/alveolar gap is grafted with a xenograft.



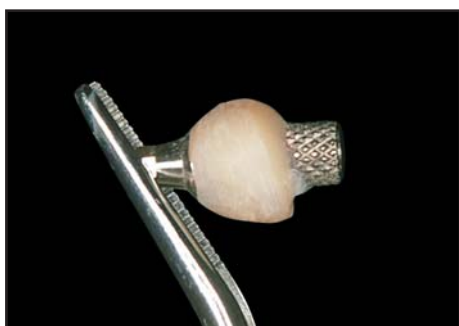**Figure 13.** The manufacturer's recommended drilling sequence was followed to the required implant depth.



**Figure 14.** The last drill is utilized to a depth equivalent to two thirds of the implant length. This allows insertion of the non-conical implant.



**Figure 15.** The implant is placed towards the palatal surface, so that a 1-mm to 2-mm gap remains between its surface and the labial wall.



**Figure 16.** A transitional custom abutment is fabricated chairside. The cervical emergence profile is similar to the corresponding area of the extracted tooth.

plane of a socket wall. Traditionally shaped initial drills and pilot burs are not designed for this application and may tend to drift during the drilling procedure, therefore making adequate implant placement more difficult in these situations (Figures 1 through 4).

The authors' preference is to utilize a precision initial drill that allows accurate positioning of the osteotomy within the palatal alveolar wall. Once the osteotomy site has been clearly established, a number of drills are followed in sequence to accommodate the desired implant length and subsequently prepare the osteotomy site to its required diameter. Efforts must be made to apply pressure towards the palatal aspect during drilling to preclude the osteotomy preparation from migrating labially as the drilling sequence is completed (Figures 5 through 12).

A common method of achieving increased insertion torques is to undersize the osteotomy preparation relative to the diameter of the implant that will be placed.<sup>19</sup> This approach, however, is not universally applicable to all implant types. Tapered implants and implants with a conical apex design exhibit a narrower apical diameter that may be fitted into an undersized osteotomy. Some popular implant designs, however, incorporate the use of parallel walls and a square or blunt apex, which do not lend themselves to common undersizing techniques.

The authors have developed a modified drilling technique to achieve higher insertion torques in implants exhibiting a non-conical design. The protocol follows the traditional drilling sequence recommended by the manufacturer except for the last drill, which must be utilized in order to properly size the osteotomy so that it will allow placement of the non-conical implant apex. Increased primary stability is achieved by drilling only to a distance corresponding to two thirds (2/3) of the implant length. The objective herein is to drill beyond the socket while preserving an underprepared portion of the osteotomy within the cancellous bone (Figures 13 through 15).

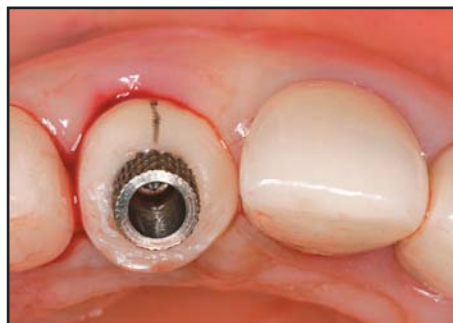Implant placement is then performed at 15 rpm, with complete seating taking place at a minimum insertion torque of 45 Ncm. In the authors' experience, the implant stability resulting from this amount of insertion torque appears to be sufficient to allow immediate placement of a provisional restoration. Depending on bone quality, excessive resistance may be encountered during implant insertion, which poses a risk of stripping the osteotomy threads. In this case, the implant must be reversed out and the osteotomy must be further prepared utilizing the final drill to a longer distance.

The osteotomy preparation is oriented to allow implant placement that will result in a gap of approximately 1 mm to 2 mm between the buccal socket wall and the corresponding implant surface. This ensures that no trauma is placed on the buccal alveolar socket wall as a result of the implant procedure. The authors advocate grafting this gap with a bovine-derived xenograft (eg, Bio-Oss, Osteohealth, Shirley, NY) regardless of periodontal biotype. The rationale is to utilize a slow-resorbing material that will provide adequate support to the gingival tissues during the postextraction bone remodeling process.<sup>20,21</sup>

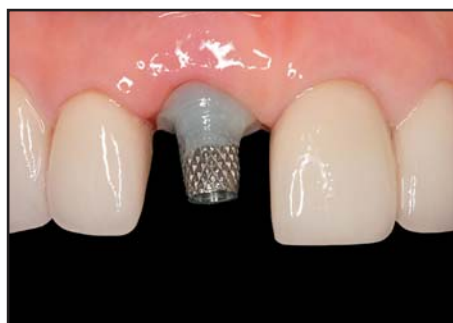### Prosthetic Guidelines

There are many techniques to fabricate an implant-supported provisional crown. The authors recommend utilizing a transitional custom abutment,<sup>16</sup> whereby composite resin is added to a metallic temporary cylinder to achieve an emergence profile that mimics the corresponding cross-sectional portion of the root (Figures 16 and 17).

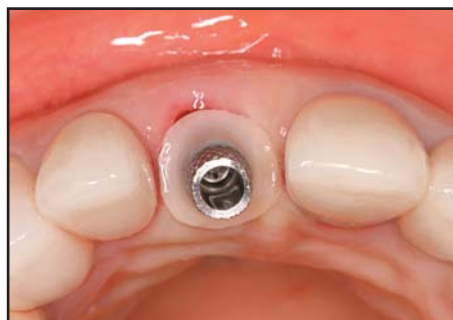Once the transitional custom abutment is fabricated, proper placement is facilitated by the fact that it is screw-retained, which allows the clinician to achieve complete seating in the presence of gingival tissue resistance. Once seated, the preparation of the transitional custom abutment is completed and a finish line is established 0.5 mm below the



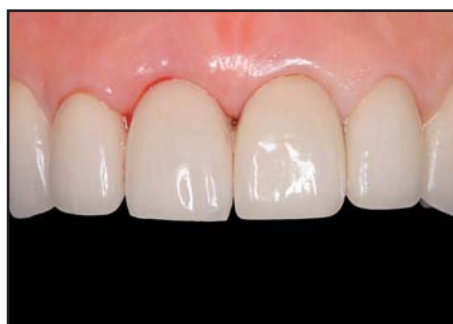**Figure 17.** The contour of the transitional custom abutment is designed to support the supracrestal tissues and preserve gingival margin levels.



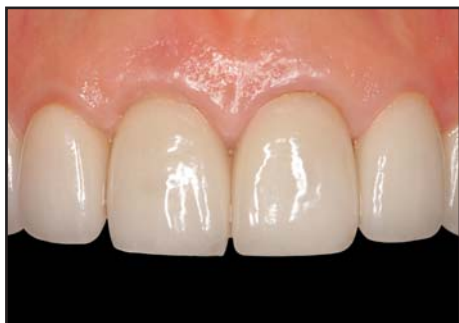**Figure 18.** Screw retention allows the transitional custom abutment to overcome soft tissue resistance.



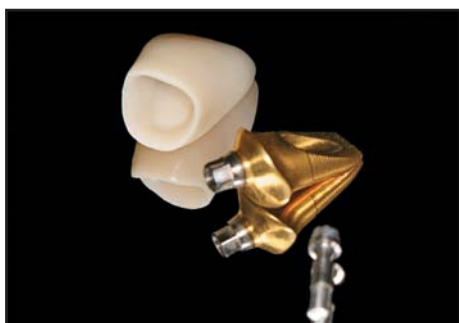
**Figure 19.** The abutment is prepared with the finish line placed 0.5 mm to 1 mm subgingivally.



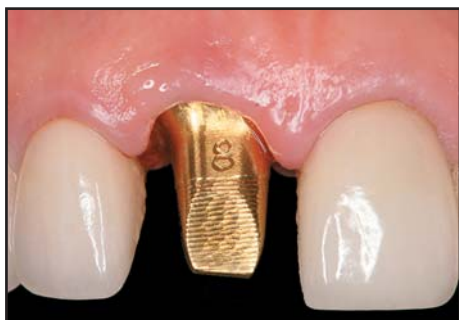**Figure 20.** The existing metal-ceramic crown is retrofitted to serve as a provisional restoration. Soft tissue stability was achieved.



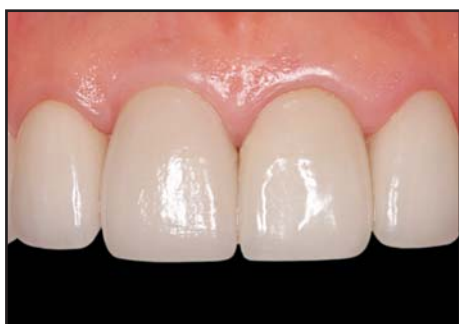**Figure 21.** Six-month postoperative appearance following immediate implant placement and provisionalization.



**Figure 22.** Restoration included a CAD/CAM-fabricated abutment and zirconia crown.



**Figure 23.** The computer-milled abutment is designed to mimic the contours of the transitional custom abutment.



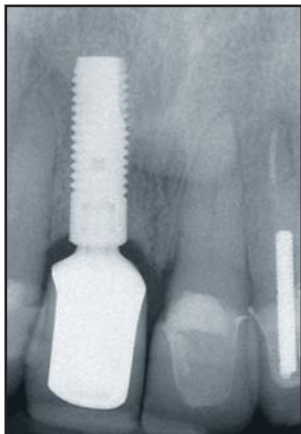
**Figure 24.** One-year postoperative appearance following placement of the definitive restoration. Papilla and gingival margin levels remain unchanged.

gingival margin. A provisional crown is subsequently fabricated and placed with temporary cement. This approach avoids the presence of a cement line within the alveolus, or in an excessively subgingival location. Additionally, it eliminates the possibility of the abutment screw exiting through the labial surface (Figures 18 through 21).

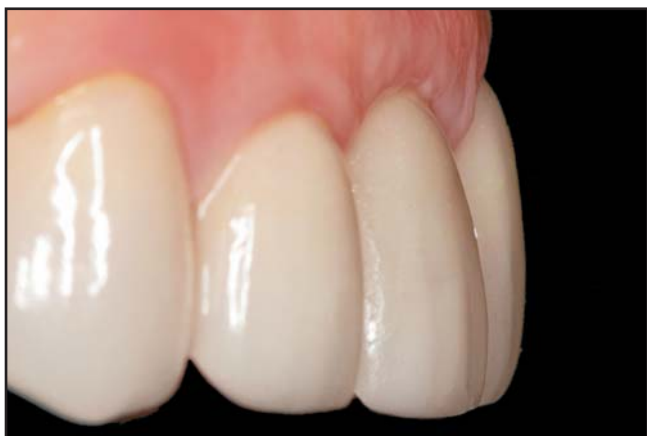Occlusal management includes relieving all centric and excursive contacts, so as to eliminate and/or minimize occlusal loading as much as possible. Patients exhibiting parafunctional habits and excessive overbite with inadequate interocclusal space are poor candidates for this technique due to the difficulty in controlling excessive loading. Following implant integration, an impression technique that utilizes the transitional custom abutment as a pick-up impression coping may be utilized to accurately replicate the peri-implant soft tissue contours.<sup>16</sup> A custom abutment may then be fabricated via casting or computer-milling techniques, over which the definitive restoration may be manufactured and placed (Figures 22 through 26).

### Future Research

Six cases were utilized in a preliminary pilot study, utilizing the modified drilling technique described above, for immediate loading of implants placed into fresh extraction sockets. No implant losses have been reported following a two-year observation period, and complete maintenance of proximal bone levels has been verified with periapical radiographs. Additionally, the peri-implant soft tissues remained stable, with post-operative changes in the labial gingival margin of less than 1 mm over the same observation period. Based on these preliminary results, a prospective clinical trial is currently under way at the University of Pennsylvania in order to further investigate the validity of this technique and its effect on peri-implant tissue predictability. The authors expect to report their results in the near future.



**Figure 25. One-year postoperative radiograph following treatment completion. Platform switching implant was effective in preserving alveolar crest levels.**



**Figure 26. Appearance at two years postoperatively. Appropriate emergence profile, maintenance of gingival margin levels, and labial soft tissue volume are evident.**

### Conclusion

Implants exhibiting a non-conical apex may be placed into fresh extraction sockets utilizing a flapless approach and immediately loaded to successfully replace individual teeth. A modified drilling sequence has been proposed to increase torque insertion and improve implant stability. Immediate placement of a provisional restoration may be essential to adequately support the peri-implant tissues. This approach may be particularly advantageous in the anterior maxilla, where maintenance of gingival margin levels is required to achieve a predictable aesthetic result.

### Acknowledgment

The authors declare no financial interest in any of the products cited herein.

### References

1. Schnitman P, Wöhrle PS, Rubenstein JE, et al. Ten-year results for Brånemark implants immediately loaded with fixed prostheses at implant placement. *Int J Oral Maxillofac Impl* 1997;12(4): 495-503.
2. Tarnow DP, Emtiaz S, Classi A. Immediate loading of threaded implants at stage 1 surgery in edentulous arches: Ten consecutive case reports with 1- to 5-year data. *Int J Oral Maxillofac Implants* 1997;12:319-324.
3. Balshi TJ, Wolfinger GJ. Immediate loading of Brånemark implants in edentulous mandibles: A preliminary report. *Implant Dent* 1997;6:83-88.
4. Ganeles J, Wismeijer D. Early and immediately restored and loaded dental implants for single-tooth and partial-arch applications. *Int J Oral Maxillofac Impl* 2005;20:769-776.
5. Testori T, Meltzer A, Del Fabbro M, et al. Immediate occlusal loading of Osseotite implants in the lower edentulous jaw: A multicenter prospective study. *Clin Oral Impl Res* 2004;15: 278-284.
6. Pietrokovskij J, Massler M. Alveolar ridge resorption following tooth extraction. *J Prosthet Dent* 1967;21-27.
7. Schropp L, Wenzel A, Kostopoulos L, Karring T. Bone healing and soft tissue contour changes following single-tooth extraction: A clinical and radiographic 12-month prospective study. *Int J Periodont Rest Dent* 2003;23:313-323.
8. Lam RV. Contour changes of the alveolar processes following extractions. *J Prosthet Dent* 1960;10:25-32.
9. Araújo MG, Lindhe J. Dimensional ridge alterations following tooth extraction. An experimental study in the dog. *J Clin Periodontol* 2005;32(2):212-218.
10. Lazzara RJ. Immediate implant placement into extraction sites: surgical and restorative advantages. *Int J Periodont Rest Dent* 1989;9(5):332-343.
11. Beagle JR. The immediate placement of endosseous dental implants in fresh extraction sites. *Dent Clin North Am* 2006;50(3): 375-389.
12. Araújo MG, Sukekava F, Wennstrom JL, Lindhe J. Tissue modeling following implant placement in fresh extraction sockets. *Clin Oral Impl Res* 2006;17:615-624.
13. Wöhrle PS. Single-tooth replacement in the aesthetic zone with immediate provisionalization: Fourteen consecutive case reports. *Pract Periodont Aesthet Dent* 1998;10:1107-1114.
14. Kan JYK, Rungcharassaeng K, Lozada J. Immediate placement and provisionalization of maxillary anterior single implants: 1-year prospective study. *Int J Oral Maxillofac Impl* 2003;18:31-39.
15. De Rouck T, Collys K, Wyn I, Cosyn J. Instant provisionalization of immediate single-tooth implants is essential to optimize esthetic treatment outcome. *Clin Oral Implants Res* 2009;20(6): 566-570.
16. Lee EA. Transitional custom abutments: Optimizing aesthetic treatment implant-supported restorations. *Pract Periodont Aesthet Dent* 1999;11(9):1027-1034.
17. Cannizaro G, Leone M, Esposito M. Immediate functional loading of implants placed with flapless surgery in the edentulous maxilla: 1-year follow-up of a single cohort study. *Int J Oral Maxillofac Implants*. 2007;22(1):87-95.
18. Pinheiro Ottoni JM, Lima Oliveira ZF, Mansini R, Cabral AM. Correlation between placement torque and survival of single-tooth implants. *Int J Oral Maxillofac Impl* 2005;20:769-776.
19. Skolak R, Zhao Y. Interaction of force-fitting and surface roughness of implants. *Clin Impl Dent Relat Res* 2000;2:219-224.
20. Araújo M, Linder E, Wennström J, Lindhe J. The influence of Bio-Oss collagen on healing of an extraction socket: An experimental study in the dog. *Int J Periodont Rest Dent* 2008;28(2):123-35.
21. Nevins M, Camelo M, De Paoli S, et al. A study of the fate of the buccal wall of extraction sockets of teeth with prominent roots. *Int J Periodont Rest Dent* 2006;26(1):19-29.



# CONTINUING EDUCATION (CE) EXERCISE No. 10



To submit your CE Exercise answers, please use the answer sheet found within the CE Editorial Section of this issue and complete as follows: 1) Identify the article; 2) Place an X in the appropriate box for each question of each exercise; 3) Clip answer sheet from the page and mail it to the CE Department at Montage Media Corporation. For further instructions, please refer to the CE Editorial Section.

The 10 multiple-choice questions for this Continuing Education (CE) exercise are based on the article "Modified drilling sequence for immediate loading of non-conical single implants placed in extraction sockets" by Ernesto A. Lee, DMD, Dr.Cir.Dent., Huan Su, DDS, and Oscar González-Martín, DDS. This article is on Pages 207-214.

1. Immediate loading is more predictable on full arches than single implants because:
  - a. Cross-arch splinting.
  - b. Anatomic variability of implant sites.
  - c. Different implant types are used.
  - d. All of the above.
2. The degree of labial alveolar crest height lost due to bone remodeling following tooth-extraction will depend on:
  - a. Whether the extracted tooth is located in the mandible or the maxilla.
  - b. Prescription of appropriate corticosteroids.
  - c. The patient's eruption sequence.
  - d. Periodontal biotype.
3. Placement of an implant into an extraction socket will prevent bone resorption.
  - a. True.
  - b. False
  - c. Remains controversial.
  - d. None of the above.
4. The mechanisms of failure for immediately loaded implants often include which of the following:
  - a. Micromotion.
  - b. Excessive fibrous tissue proliferation along the implant surface.
  - c. Inadequate bone-to-implant contact.
  - d. All of the above.
5. According to published studies, what is the minimum insertion torque required for immediate loading of single implants?
  - a. 15 Ncm.
  - b. 45 Psi.
  - c. 90 Ncm.
  - d. 45 Ncm.
6. What is the advantage of immediate provisionalization following implant placement into an extraction socket?
  - a. Improved patient management.
  - b. Support of the supracrestal soft tissues.
  - c. Maintenance of papilla and peri-implant tissue levels.
  - d. All of the above.
7. What is the principal advantage of using a transitional custom abutment?
  - a. Enhanced control of restorative contours and emergence profile.
  - b. Time saving.
  - c. Cost efficiency.
  - d. Allows use of a cemented provisional.
8. What is the purpose of initiating the osteotomy with the precision drill?
  - a. Enhanced visibility.
  - b. Allows drilling at much faster speeds.
  - c. Precise drilling on the incline of a socket wall.
  - d. No need to use subsequent drills.
9. How is the drilling sequence modified to enhance primary stability if the implant does not have a conical apex?
  - a. Undersize the osteotomy by not using the final drill at all.
  - b. Underprepare the apical 1/3 of the osteotomy by using the final drill to 2/3 the implant length.
  - c. Reverse the drilling sequence.
  - d. None of the above.
10. Why is the implant oriented towards the palate, leaving a labial gap of 1 mm to 2 mm?
  - a. To avoid touching the labial gingival margin.
  - b. To ensure that the abutment screw will exit through the lingual surface.
  - c. To avoid trauma to the buccal plate throughout the implant procedure.
  - d. To provide sufficient space for a grafting material.